

Bilateral Descemet's stripping with endothelial keratoplasty for posterior polymorphous corneal dystrophy in a young phakic patient

Endothelial keratoplasty has been popularized as an alternative to penetrating keratoplasty for the treatment of corneal endothelial dysfunction.¹ Cataract formation has been reported to occur in up to 7.4% of phakic eyes after endothelial keratoplasty.¹ Most surgeons offer lensectomy or cataract extraction in combination with or prior to endothelial transplantation. However, in younger individuals with preserved accommodation, lensectomy is controversial. We report bilateral Descemet's stripping with endothelial keratoplasty (DSEK) in a young female with posterior polymorphous dystrophy (PPMD).

A 12-year-old female with PPMD was referred for keratoplasty. Visual acuity had been decreasing progressively since age 9. At presentation, best-corrected visual acuity (BCVA) was 20/200 OU. Central corneal pachymetry measurements were 722 μm and 736 μm OD and




Fig. 1—Preoperative slit lamp view of the right cornea showing stromal edema, as well as vesicular and linear-shaped lesions of the posterior cornea.

OS, respectively. Slit-lamp examination showed corneal edema, as well as vesicular and linear-shaped lesions of the posterior cornea (Fig. 1). Findings were more prominent in the right eye, where evidence of stromal scarring due to chronic edema was noted. Examination of the patient's fundi was unremarkable. This patient's school, sporting, and general activities were hampered by her level of visual acuity.

DSEK was performed using several modifications to our routine methods. Pilocarpine 2% was instilled preoperatively to provide additional protection of the lens. The procedure was performed under general anaesthesia because of the patient's young age. This allowed better control of posterior vitreous pressure by providing a state of systemic and ocular hypotension, which was further aided by the use of 20% mannitol solution intravenously. Because of the potential for pilocarpine to produce anterior iris–lens diaphragm displacement, pressure was applied to the globe using a mercury bag for 5 minutes preoperatively to induce further ocular hypotony. The posterior lamellar donor lenticule was dissected manually.² DSEK was performed first in the right eye using the approach described by Terry et al.³ The stripping procedure was noted to be considerably more difficult than we had previously experienced in conditions such as Fuchs' endothelial dystrophy. The right eye, which also had more advanced disease and more preoperative scarring, was more difficult to dissect

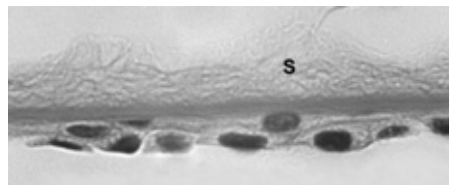


Fig. 2—The Descemet's stripping with endothelial keratoplasty specimen shows a multilayered, epithelial-like appearance of the corneal endothelium adjacent to Descemet's membrane and the posterior corneal stroma (S). (Periodic acid-Schiff, original magnification $\times 640$.)

than the left eye. The donor tissue was directed away from the pupil during insertion. Because of the risk of retching or inadvertent movements while the patient was waking from the anaesthetic, only minimal air–fluid exchange was performed, and all wounds were sutured using 10-0 nylon. Seven months later, the left eye was operated on in a similar fashion.

Histopathological examination of the DSEK specimen revealed partial-thickness posterior corneal stroma in continuity with Descemet's membrane (Fig. 2). The corneal endothelium showed focal areas of multilayered, epithelial-like cells compatible with PPMD.

The postoperative course was uneventful for both eyes, and after 1 year BCVA was 20/80 OD and 20/30 OS. There has been no cataract formation in either eye. The reduced acuity in the right eye has been attributed to the stromal scarring and, given the asymmetric preoperative findings, amblyopia also was suspected. Functionally, this patient improved her performance at school and became involved in sports once again.

REFERENCES

1. Price FW Jr, Price MO. Descemet's stripping with endothelial keratoplasty in 200 eyes: early challenges and techniques to enhance donor adherence. *J Cataract Refract Surg* 2006;32:411–8.
2. Bower T, Rocha G. Use of a disposable artificial anterior chamber for trans-epithelial trephination and endothelial keratoplasty. *Tech Ophthalmol* 2007;5:21–6.
3. Terry MA, Shamie N, Chen ES, et al. Endothelial keratoplasty for Fuchs' dystrophy with cataract: complications and clinical results with the new triple procedure. *Ophthalmology* 2009; 116:631–9.

**Michel J. Belliveau,* Guillermo Rocha,*[†]
Andrea Manchur,[‡] Seymour Brownstein***

**University of Ottawa, Ottawa, Ont., [†]Brandon Regional Health Centre, Brandon, Man., and [‡]School of Optometry, Waterloo, Ont.*

Correspondence to Seymour Brownstein, MD: sbrownstein@obri.ca

Can J Ophthalmol 2010;45:180–1
doi:10.3129/i09-199